

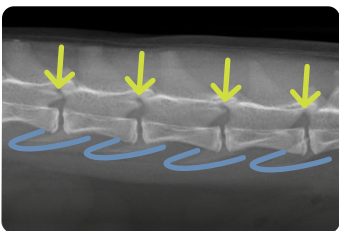
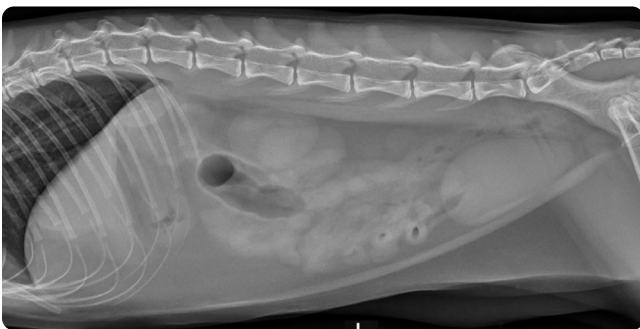

Technical Tips

Radiography: Abdomen

Include All Palpate Landmarks

- ✓ Center about 13th rib
- ✓ Xiphoid +4 fingers cranial for entire liver
- ✓ Spinous processes and ventral sternum
- ✓ Greater trochanter of hip

Lateral View (Take on Expiration)

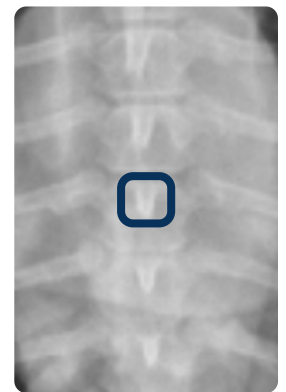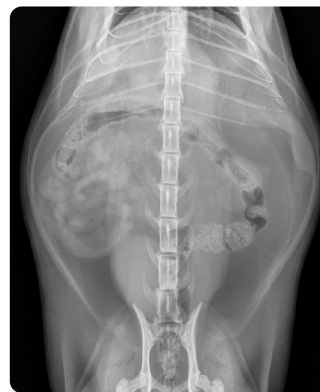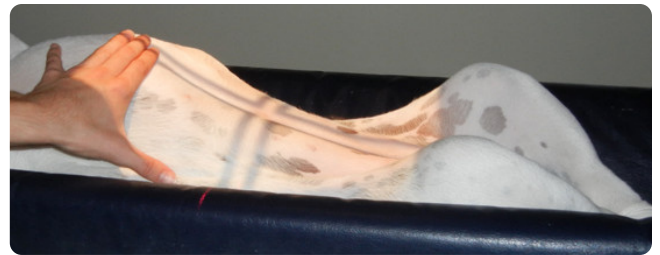


- "Horse heads" at lumbar disc spaces
- Transverse processes superimposed

Urinary History

- ✓ Include all caudal soft tissue to visualize urethra
- ✓ In male dogs, add flexed lateral view
- ✓ In cats and female dogs, be sure to include entire perineal region to evaluate entire urethra

VD View (Take on Expiration)



- ✓ Avoid rotation
- ✓ Center the spinal column

- Spinous process

Images courtesy of Danielle Mauragis, CVT, Radiology, University of Florida, 2015.