

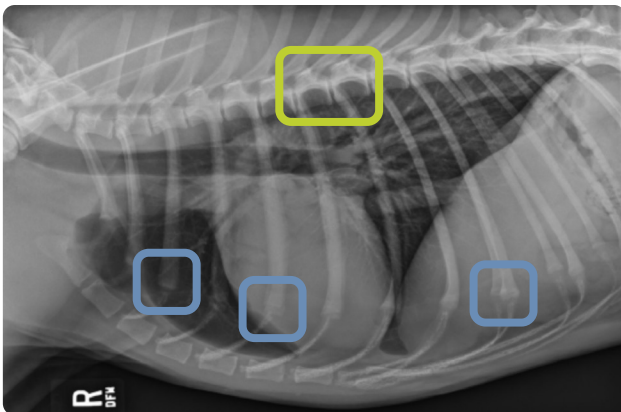
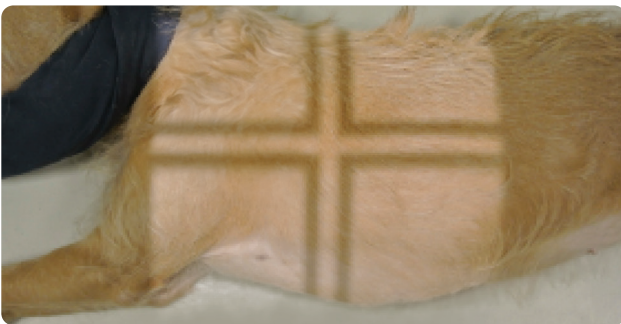
Technical Tips

Radiography: Thorax

Include All Palpate Landmarks

- ✓ Center on the heart beat
- ✓ Caudal edge of scapula
- ✓ Manubrium for lung margin
- ✓ Sternum +4 finger widths for caudal lung tips

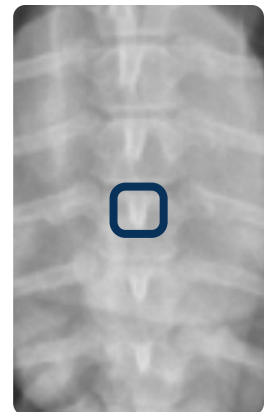
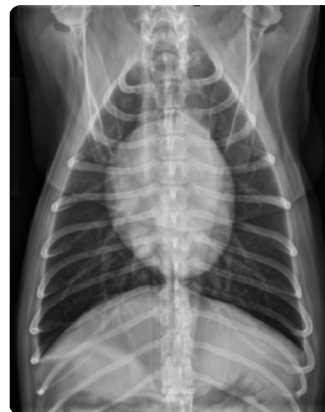Lateral View



- Rib heads are superimposed
- Costochondral junction in same place

Images courtesy of Danielle Mauragis, CVT, Radiology, University of Florida, 2015.

VD or DV View



- ✓ Avoid rotation
- ✓ Center the spinous processes in the spinal column
- Spinous process